



## ORIGINAL ARTICLE

# Fungal prostatitis due to endemic mycoses and *Cryptococcus*: A multicenter case series

David J. Epstein MD<sup>1</sup>  | Lester D. R. Thompson MD<sup>2</sup> | Atif Saleem DO<sup>3</sup> | Chia-Sui Kao MD<sup>3</sup> | Jonathan I. Epstein MD<sup>4</sup> 

<sup>1</sup>Division of Infectious Diseases and Geographic Medicine, Department of Medicine, Stanford University School of Medicine, Stanford, California

<sup>2</sup>Department of Pathology, Southern California Permanente Medical Group, Pasadena, California

<sup>3</sup>Department of Pathology, Stanford University School of Medicine, Stanford, California

<sup>4</sup>Department of Pathology, Johns Hopkins Medical Institutions, Baltimore, Maryland

## Correspondence

David J. Epstein, MD, Division of Infectious Diseases and Geographic Medicine, Department of Medicine, Stanford University School of Medicine, 300 Pasteur Drive, Lane Building, Mail Code 5107, Stanford, CA 94305. Email: [depstein@stanford.edu](mailto:depstein@stanford.edu)

## Abstract

**Background:** Fungal prostatitis is exceedingly rare with mostly case reports.

**Methods:** Electronic medical records at three medical centers were searched for cases of fungal prostatitis due to endemic mycoses and *Cryptococcus* over the preceding 10 years.

**Results:** Seven cases were identified from 105 600 prostate biopsies within the Southern California Permanente Medical Group for an incidence of 0.0066%. An additional eight cases were identified from two other health care systems. Excluding four patients without available clinical data, 11 patients were reviewed, most of whom underwent biopsy due to elevated prostate-specific antigen. Four were asymptomatic and the remainder had nonspecific signs or symptoms. All biopsies revealed granulomatous inflammation and fungal organisms. Seven patients had coccidioidomycosis, three patients had cryptococcosis (confirmed in two cases and suspected by organism morphology in the other), and one patient had likely histoplasmosis based on organism morphology. Prolonged antifungal treatment was standard; outcomes were favorable.

**Conclusion:** Fungal prostatitis due to endemic mycoses and *Cryptococcus* is uncommon and associated with favorable outcomes but generally involves prolonged therapy.

## KEYWORDS

coccidioidomycosis, fungal prostatitis, fungi, mycoses, prostate cryptococcosis, prostate histoplasmosis, prostate infections

## 1 | INTRODUCTION

While most diseases of the prostate are due to neoplasia or infection with typical bacterial pathogens (in the cases of acute or chronic bacterial prostatitis), fungi can also infect the prostate. Fungal prostatitis can be due to *Candida* species in the context of candidemia or an ascending urinary tract infection, but endemic mycoses, so named because of their geographic restriction, and *Cryptococcus*, a more widely distributed yeast, are underappreciated causes of infectious prostatitis.<sup>1</sup> Endemic mycoses typically include species in the genera *Coccidioides*, *Histoplasma*, *Blastomyces*, and *Paracoccidioides*.

While *Cryptococcus* is not thermally dimorphic nor geographically restricted, it often causes similar clinical syndromes, including primary pulmonary infection with occasional extrapulmonary dissemination. Moreover, both *Cryptococcus* and endemic mycoses are often associated with characteristic epidemiologic risk factors.

Though case reports of fungal prostatitis due to endemic mycoses and *Cryptococcus* have been published, along with at least one small case series of prostatitis due to *Coccidioides*, to our knowledge there has no multicenter case series of these infections.<sup>2</sup> Despite being relatively uncommon, these infections are often difficult to diagnose and may be associated with significant morbidity. We

report a case series of prostatitis due to endemic mycoses and *Cryptococcus* from three institutions.

## 2 | MATERIAL AND METHODS

Our three institutions review large numbers of prostate biopsies annually. Two institutions (Stanford University School of Medicine and Johns Hopkins School of Medicine) are associated with large medical centers and review prostate biopsy specimens and slides from procedures performed locally as well as through consultative requests from regional and national health care systems. The third institution (Southern California Permanente Medical Group) is a large integrated health care organization with ~4.2 million members within Southern California. Seven of the cases were identified in a systematic review of 105 600 prostate specimens obtained from 2007 to 2017 within the Southern California Permanente Medical Group's 12 medical centers, giving an incidence of 0.0066% of all patients with prostate biopsies. Institutional review board approval was obtained from each institution. Stanford IRB #47341; SCPMG IRB #11688; Johns Hopkins IRB #00184664. Electronic medical record systems were searched for cases within the past 10 years (beginning in 2007) with fungal prostatitis due to organisms from the genera *Coccidioides*, *Histoplasma*, *Blastomyces*, *Paracoccidioides*, *Penicillium*, and *Cryptococcus*. Infections due to *Candida* species and other non-*Cryptococcus* yeasts and molds with nonthermally dimorphic lifecycles (such as *Aspergillus* species) were excluded. Patients must have met established criteria for proven diagnosis with an endemic mycosis or cryptococcosis.<sup>3</sup>

In addition to histopathologic features, patient information including demographics, clinical history, laboratory and microbiologic studies, imaging, treatment course, and outcome was collected. Patients whose clinical information was unable to be obtained were excluded. While histopathology can identify presence of fungal organisms and suggest the likely causative genus or species, histopathologic diagnosis is notoriously inaccurate and generally requires additional diagnostic testing or clinical input.<sup>4</sup> Relevant microbiologic data included serologic assays (such as *Coccidioides* immunodiffusion and complement fixation titers, *Histoplasma* antigen or antibody assays, and cryptococcal antigen assays), fungal culture and phenotypic identification, and molecular identification. At one institution (Stanford Health Care), fungal identification by molecular sequencing is routinely employed in cases of suspected or proven fungal infection.<sup>5</sup>

## 3 | RESULTS

Out of 15 cases of prostatitis due to endemic mycoses and *Cryptococcus*, corresponding clinical information was available for 11 cases which were included in our analysis (Table 1). Of the remaining four patients without corresponding clinical data, three had organisms morphologically consistent with *Coccidioides* and one had an organism morphologically consistent with *Cryptococcus*. All specimens

were obtained from core needle biopsies except for one specimen obtained via radical prostatectomy after an initial needle biopsy demonstrated carcinoma only without granulomatous inflammation or fungal organisms. The patients ranged in age from 43 to 79 years (median 57 years) and lived in California, Alabama, Arkansas, New Jersey, and Nebraska. The most common indication for prostate biopsy was elevated prostate-specific antigen (PSA). Four patients were entirely asymptomatic; the remaining patients had lower urinary tract symptoms, dysuria, hematuria, or testicular pain. With the exception of one patient with weight loss, fever, rigors, or other systemic complaints were absent. The results of physical examination and imaging (ultrasound or magnetic resonance imaging), when performed, were normal or nonspecific as to the cause of patients' elevated PSA or symptoms. Among the nine patients with available white blood cell counts, none had leukocytosis. Among the five patients with erythrocyte sedimentation rate (ESR) and C-reactive protein studies available, all had normal values except for one patient with a slightly elevated ESR of 32 mm/h. Microscopic or dipstick urinalysis was available for nine patients and was normal in five; the remainder had either minimal pyuria (with no patient having more than 10 white blood cells per high-power field), glycosuria, or hematuria. Of the eight patients with available PSA results, seven had elevated PSA levels, with a median level of 13.0 ng/mL.

All biopsies revealed necrotizing or non-necrotizing granulomatous inflammation along with fungal organisms. Coccidioidomycosis was definitively diagnosed in seven patients, all of whom had histopathology results showing organisms consistent with *Coccidioides* as well as positive *Coccidioides* serologies (with complement fixation titers ranging from 1:4 to 1:32) (Figure 1). In one patient, the organism was identified by molecular sequencing. Two patients had confirmed cryptococcosis based on organism morphology and either positive serum cryptococcal antigen or growth of *Cryptococcus* from another body site (Figure 2). Two patients had confirmed fungal prostatitis though the organism could not be definitively identified, including one patient who was diagnosed with likely histoplasmosis based on compatible organism morphology though a *Histoplasma* serum antibody was negative and another who was diagnosed with likely cryptococcosis though a serum cryptococcal antigen was negative. Adenocarcinoma was identified in three patients and atypical glands were identified in an additional three patients.

Three of the seven patients with coccidioidomycosis had a known history of this infection; all of these patients had either prior or concurrent pulmonary disease. One patient with coccidioidomycosis was African American; the others were White. All patients with coccidioidomycosis lived in California, except for one who lived in the Midwestern United States at the time of the diagnosis but had lived in California for many years earlier in his life. On review of medical records, this patient presented with fevers and consolidations on chest radiography many years before when he lived in California; coccidioidomycosis commonly presents as community-acquired pneumonia and is often undiagnosed. Another patient with coccidioidomycosis had involvement of the testicle and underwent an orchiectomy. Diabetes mellitus was present in three of the patients

**TABLE 1** Clinicopathologic findings

Age (y)	Significant history or comorbidities	Presenting signs and symptoms	Histopathology	Adenocarcinoma or atypia	Microbiologic data	Treatment and outcome
Coccidioidomycosis						
53	None	Elevated PSA; asymptomatic; prior needle biopsy with carcinoma	Prostatectomy specimen; necrotizing granulomas; spherules consistent with <i>Coccidioides</i>	Adenocarcinoma; 3 + 3 = 6	Molecular sequencing identified <i>Coccidioides</i> ; Coccidioides CF 1-8 and 1:32 on repeat	Fluconazole for several months; prolonged follow-up not available
64	History of pulmonary coccidioidomycosis 5 y prior	Elevated PSA; LUTS; mild pyuria	Granulomatous and mixed inflammation; spherules consistent with <i>Coccidioides</i>	None	Coccidioides CF 1:32	Fluconazole for 5 y
52	DM; CKD; substance-use disorder	Elevated PSA; intermittent hematuria	Acute and chronic inflammation and noncaseating granulomas; spherules consistent with <i>Coccidioides</i>	Few atypical glands consistent with atypical small acinar proliferation	Coccidioides CF 1:8	Fluconazole for 2 y
72	None	Elevated PSA; asymptomatic	Non-necrotizing granulomas; spherule consistent with <i>Coccidioides</i>	Adenocarcinoma; 3 + 3 = 6	Coccidioides CF 1:32	Fluconazole for 9 y
43	History of pulmonary coccidioidomycosis 6 y prior; substance-use disorder and alcoholism	Elevated PSA; asymptomatic	Acute and chronic inflammation; spherules with endospores consistent with <i>Coccidioides</i>	None	Coccidioides CF 1:16	Fluconazole for 11 mo
79	DM; CKD; Alzheimer's disease	Elevated PSA; asymptomatic	Non-necrotizing granulomas; spherules consistent with <i>Coccidioides</i>	None	Coccidioides CF 1:4	Fluconazole for ≥8 mo; orchiectomy for testicular <i>Coccidioides</i> involvement
58	History of pulmonary coccidioidomycosis 5 y prior; DM; CKD; cardiomyopathy; obesity	Elevated PSA; LUTS; mild pyuria	Non-necrotizing and necrotizing granulomas; spherules with endospores consistent with <i>Coccidioides</i>	Adenocarcinoma; 3 + 3 = 6	Coccidioides CF 1:4	Fluconazole for 11 mo
Cryptococcosis						
56	History of kidney transplant 18 y prior (on azathioprine and prednisone)	Elevated PSA; LUTS; glycosuria and hematuria	Granulomas; fungal organisms consistent with <i>Cryptococcus</i>	None	<i>Cryptococcus</i> identified in CSF	Unknown
57	Rheumatoid arthritis on methotrexate and infliximab; recurrent herpes zoster	Elevated PSA; dysuria	Granulomas; fungal organisms consistent with <i>Cryptococcus</i>	Small focus of atypical glands highly suspicious for carcinoma	Serum cryptococcal antigen 1:8	Fluconazole for 2 mo
47	HIV with T-lymphocytes of 350 cells/ $\mu$ L on antiretroviral therapy; history of cryptococcal meningitis 4 y prior	LUTS; weight loss; hematuria	Fungal organisms with capsule stain likely <i>Cryptococcus</i>	None	Serum cryptococcal antigen negative	Fluconazole for ≥3 y

(Continues)

TABLE 1 (Continued)

Age (y)	Significant history or comorbidities	Presenting signs and symptoms	Histopathology	Adenocarcinoma or atypia	Microbiologic data	Treatment and outcome
61	None	Testicular pain; BPH	Granulomas; intracellular budding yeast consistent with <i>Histoplasma</i>	Small focus of atypical glands suspicious for carcinoma	<i>Histoplasma</i> antibody negative	Itraconazole for 3 mo

Abbreviations: BPH, benign prostatic hyperplasia; CF, complement fixation; CKD, chronic kidney disease; DM, diabetes mellitus; HIV, human immunodeficiency virus; LUTS, lower urinary tract symptoms; PSA, prostate-specific antigen.

with coccidioidomycosis; other comorbidities present in more than one patient included chronic kidney disease and alcoholism or substance-use disorder.

All three patients with cryptococcosis were immunocompromised: one was status post renal transplantation and remained on immunosuppression; another was being treated with infliximab and other medications for rheumatoid arthritis; and the third patient had human immunodeficiency virus (HIV) infection with a T-lymphocyte count of ~350 cells/ $\mu$ L while on antiretroviral therapy. The renal transplant patient had concomitant cryptococcal meningitis and the patient with HIV had cryptococcal meningitis approximately 4 years earlier. The patient with presumed histoplasmosis was healthy, although he lived in an area of moderate to high *Histoplasma* endemicity.

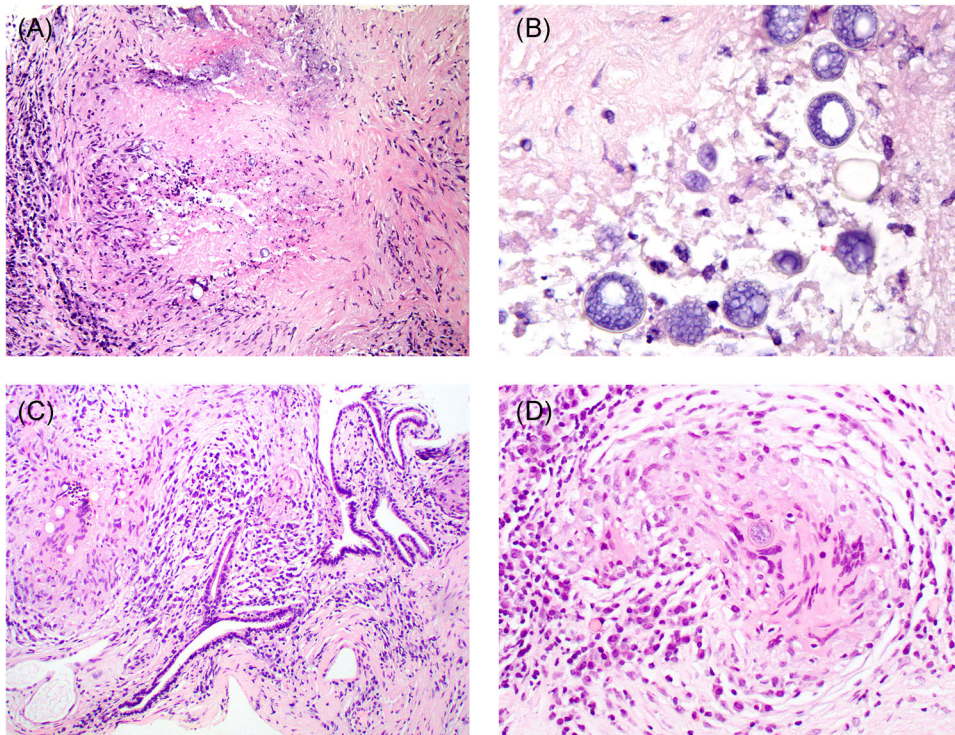
Patients with coccidioidomycosis were generally treated with fluconazole for durations ranging from several months to several years. Itraconazole or fluconazole was used to treat patients with presumed histoplasmosis or cryptococcosis, generally for shorter durations. Outcomes were generally favorable though some patients remain on treatment at the time of data collection. No patient deaths were identified.

## 4 | DISCUSSION

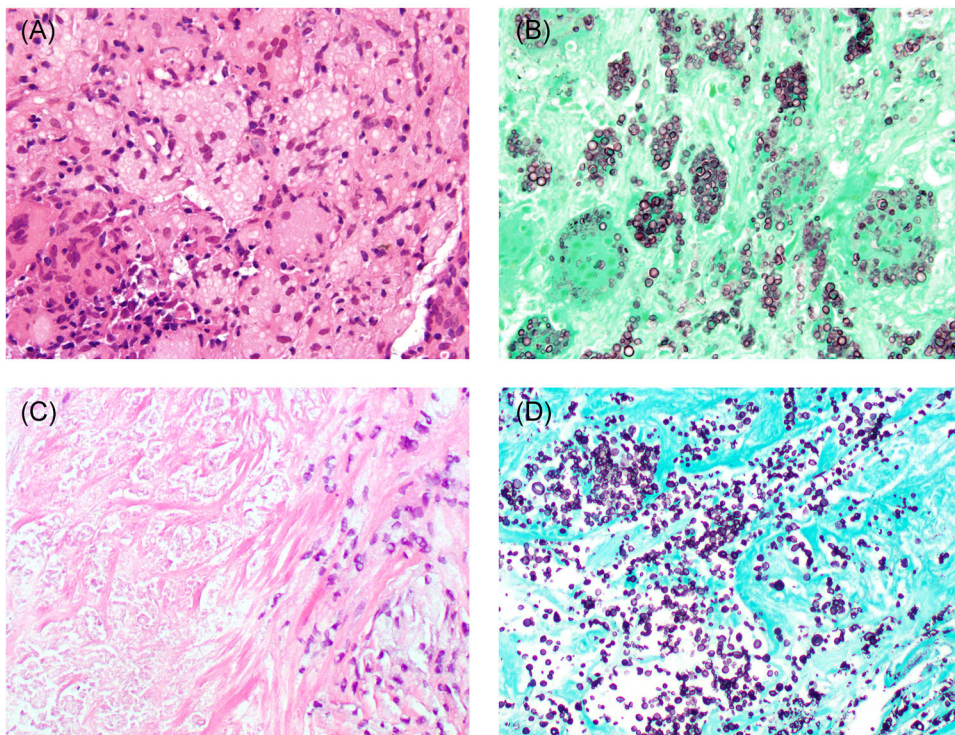
No case series of fungal prostatitis due to endemic mycoses and *Cryptococcus* have been published to our knowledge in over a decade. Two prior case series published in 2005 and 2006 focused exclusively on coccidioidomycosis and were both single-center studies from Arizona.<sup>2,6</sup> One case series identified four patients with prostatitis due to *Coccidioides* out of 3676 specimens between 1994 and 2000, yielding an incidence of 0.11% during this period or 0.02% per year.<sup>2</sup> Two patients were untreated and reportedly did well and two other patients were treated (though one died of disseminated coccidioidomycosis despite aggressive antifungal therapy).<sup>2</sup> The other case series also identified four patients with *Coccidioides* prostatitis (in addition to other patients with nonprostatic genitourinary *Coccidioides* infections).<sup>6</sup> As in our study, pulmonary coccidioidomycosis was sometimes seen as well and patients presented with indolent disease and were often asymptomatic; one patient was monitored without treatment.<sup>6</sup> A recent case report and literature review found 70 reported cases of prostatic cryptococcosis since the 1940s, also mostly in immunocompromised patients with frequent dissemination.<sup>7</sup> Prostatic blastomycosis and paracoccidioidomycosis have been reported only rarely.<sup>8-10</sup>

*Coccidioides*, *Histoplasma*, and *Cryptococcus* were identified as etiologic agents of fungal prostatitis in this multicenter case series. As evidenced by patients' clinical presentations, these infections are impressively indolent. Leukocytosis, elevations in inflammatory markers, or pyuria, typical markers of systemic, or genitourinary tract infection, were often absent or muted. In fact, most of these infections were discovered incidentally during biopsies for patients with elevated PSA being evaluated for malignancy. Most patients had no concurrent extraprostatic loci of infection though some had prior known fungal infections. Coccidioidomycosis was particularly common in our case series, perhaps reflecting that two of the three centers in this study were in California, and





**FIGURE 1** Necrotizing granulomas on prostate needle biopsy (A) with higher magnification (B) showing mature spherules with outer thick wall and numerous endospores. Another case showing non-necrotizing granulomas adjacent to intact prostate glands (C). Higher magnification (D) shows a single spherule [Color figure can be viewed at [wileyonlinelibrary.com](http://wileyonlinelibrary.com)]



**FIGURE 2** Granulomatous prostatitis with numerous multinucleated histiocytes containing pale vacuoles with suggestion of features suspicious for *Cryptococcus* (A). Gomori Methenamine-Silver (GMS) stain shows numerous cryptococcal forms (B) in histiocytes. Prostate with necrosis (right) (C). GMS stain shows numerous cryptococcal forms (D) in tissue [Color figure can be viewed at [wileyonlinelibrary.com](http://wileyonlinelibrary.com)]

affected patients who were generally healthy. That our calculated incidence of coccidioidomycosis from Southern California was substantially lower than calculated by the aforementioned Arizona-based study may reflect differences in regional epidemiology. While those of African or Filipino descent are thought to be at higher risk of disseminated coccidioidomycosis, most of the patients in this series with prostatitis due to *Coccidioides* were White.<sup>11</sup> Unlike those with coccidioidomycosis, all patients with cryptococcal prostatitis in our case series had profoundly impaired cellular immunity due to HIV infection, solid organ transplantation, or use of anti-inflammatory monoclonal antibody drugs, suggesting that disseminated infections due *Cryptococcus* are more likely in immunocompromised patients. Relatively prolonged treatment with systemic antifungals led to generally favorable outcomes.

Ours is the only comprehensive case series of patients with fungal prostatitis due to endemic mycoses and *Cryptococcus* to our knowledge, and includes a diversity of institutions, including a large integrated health care organization and two referral medical centers. While histoplasmosis and coccidioidomycosis are nationally notifiable conditions, others (such as blastomycosis, cryptococcosis—except infections due to *C. gattii*—and paracoccidioidomycosis) are not.<sup>12</sup> Given these limited data, case series such as ours are critical in discerning the presentation, diagnostic methods, and treatment patterns for these infections. As a case series, our data cannot be used to calculate the incidence of fungal prostatitis due to these mycoses. Moreover, the distribution of particular fungal etiologies may reflect a sampling bias, particularly since two of our three institutions are in California and since certain consultative requests may not be made equally for all types of fungal prostatitis. Finally, in two cases, definitive identification of the fungal genus or species could not be made given negative serologic evaluation.

Given an apparent increase in coccidioidomycosis in the American West and Southwest, cases of fungal prostatitis due to *Coccidioides* may increase as well.<sup>13,14</sup> Moreover, while new cases of HIV are declining, the array of potent immunosuppressive drugs for malignant and autoimmune conditions continues to grow, which may place patients at increased risk of disseminated cryptococcosis and other infections. As cryptococcosis and infections due to endemic mycoses are often multi-system diseases with hematogenous dissemination, providers should carefully evaluate patients for disease involvement outside the genitourinary tract.

## 5 | CONCLUSIONS

Fungal prostatitis due to endemic mycoses and *Cryptococcus* is uncommon but has important clinical implications. Prostatic coccidioidomycosis and histoplasmosis can occur in otherwise healthy individuals though prostatitis due to *Cryptococcus* is likely more common among patients with profoundly compromised immunity. Patients often present asymptotically or with minimal symptoms; classic signs and symptoms of infection are uncommon and laboratory studies and imaging are often normal or unimpressive. Treatment with prolonged antifungal therapy is associated with favorable outcomes.

## CONFLICT OF INTERESTS

All the authors declare that there are no conflict of interests.

## ORCID

David J. Epstein  <https://orcid.org/0000-0002-8541-2623>

Jonathan I. Epstein  <http://orcid.org/0000-0003-1839-6472>

## REFERENCES

1. Kauffman CA, Fisher JF, Sobel JD, Newman CA. Candida urinary tract infections—diagnosis. *Clin Infect Dis*. 2011;52(Suppl 6):S452-S456.
2. Yurkanin JP, Ahmann F, Dalkin BL. Coccidioidomycosis of the prostate: a determination of incidence, report of 4 cases, and treatment recommendations. *J Infect*. 2006;52(1):e19-e25.
3. De Pauw B, Walsh TJ, Donnelly JP, et al. Revised definitions of invasive fungal disease from the European Organization for Research and Treatment of Cancer/Invasive Fungal Infections Cooperative Group and the National Institute of Allergy and Infectious Diseases Mycoses Study Group (EORTC/MSG) Consensus Group. *Clin Infect Dis*. 2008;46(12):1813-1821.
4. Guarner J, Brandt ME. Histopathologic diagnosis of fungal infections in the 21st century. *Clin Microbiol Rev*. 2011;24(2):247-280.
5. Gomez CA, Budvytiene I, Zemek AJ, Banaei N. Performance of targeted fungal sequencing for culture-independent diagnosis of invasive fungal disease. *Clin Infect Dis*. 2017;65(12):2035-2041.
6. Sohail MR, Andrews PE, Blair JE. Coccidioidomycosis of the male genital tract. *J Urol*. 2005;173(6):1978-1982.
7. Shah SI, Bui H, Velasco N, Rungta S. Incidental finding of *Cryptococcus* on prostate biopsy for prostate adenocarcinoma following cardiac transplant: case report and review of the literature. *Am J Case Rep*. 2017;18:1171-1180.
8. Watts B, Argekar P, Saint S, Kauffman CA. Clinical problem-solving. Building a diagnosis from the ground up—a 49-year-old man came to the clinic with a 1-week history of suprapubic pain and fever. *N Engl J Med*. 2007;356(14):1456-1462.
9. Neal PM, Nikolai A. Systemic blastomycosis diagnosed by prostate needle biopsy. *Clin Med Res*. 2008;6(1):24-28.
10. de Arruda PF, Gatti M, de Arruda JG, et al. Prostatic paracoccidioidomycosis with a fatal outcome: a case report. *J Med Case Rep*. 2013;7:126.
11. Galgiani JN, Ampel NM, Blair JE, et al. 2016 Infectious Diseases Society of America (IDSA) clinical practice guideline for the treatment of coccidioidomycosis. *Clin Infect Dis*. 2016;63(6):e112-e146.
12. Centers for Disease Control and Prevention. Surveillance Case Definitions for Current and Historical Conditions 2017 [02/11/2019]. <https://wwwn.cdc.gov/nndss/conditions/>. Accessed June 18, 2020.
13. Cooksey GS, Nguyen A, Knutson K, et al. Notes from the field: increase in coccidioidomycosis - California, 2016. *MMWR Morb Mortal Wkly Rep*. 2017;66(31):833-834.
14. Bezold CP, Khan MA, Adame G, Brady S, Sunenshine R, Komatsu K. Notes from the field: increase in coccidioidomycosis - Arizona, October 2017-March 2018. *MMWR Morb Mortal Wkly Rep*. 2018;67(44):1246-1247.

**How to cite this article:** Epstein DJ, Thompson LDR, Saleem A, Kao C-S, Epstein JI. Fungal prostatitis due to endemic mycoses and *Cryptococcus*: A multicenter case series. *The Prostate*. 2020;1-6. <https://doi.org/10.1002/pros.24034>